
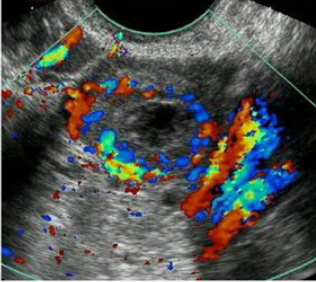




Normal Appearance		Follow-up*	Comments
Normal ovary appearance: Reproductive age Follicles <ul style="list-style-type: none"> • Thin and smooth walls • Round or oval • Anechoic • Size \leq 3 cm • No blood flow 		Not needed	Developing follicles and dominant follicle \leq 3 cm are normal findings
Normal ovary appearance: Reproductive age Corpus luteum <ul style="list-style-type: none"> • Diffusely thick wall • Peripheral blood flow • Size \leq 3 cm • +/- internal echoes • +/- crenulated appearance 		Not needed	Corpus luteum \leq 3 cm is a normal finding
Normal ovary appearance: Postmenopausal <ul style="list-style-type: none"> • Small • Homogenous 		Not needed	Normal postmenopausal ovary is atrophic without follicles
Clinically inconsequential: Postmenopausal Simple cyst \leq 1 cm <ul style="list-style-type: none"> • Thin wall • Anechoic • No flow 		Not needed	Small simple cysts are common; cysts \leq 1 cm are considered clinically unimportant