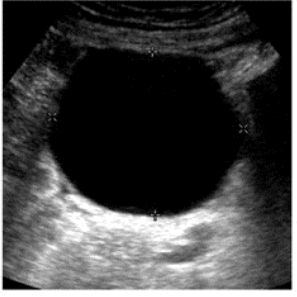

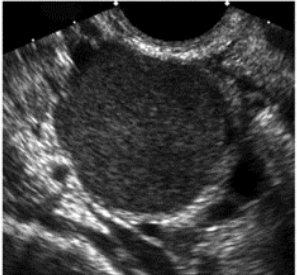
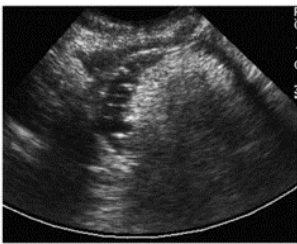

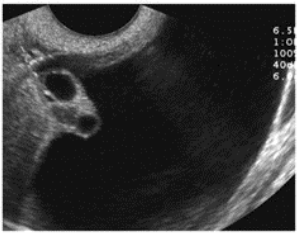


| Cysts with benign characteristics | | Follow-up* | Comments |
|--|---|---|---|
| <p>Simple cysts (includes ovarian and extraovarian cysts)</p> <ul style="list-style-type: none"> • Round or oval • Anechoic • Smooth, thin walls • No solid component or septation • Posterior acoustic enhancement • No internal flow |  | <p>Reproductive age: ≤ 5 cm: Not needed > 5 & ≤ 7cm: Yearly</p> <p>Postmenopausal (PM): > 1 & ≤ 7 cm: Yearly**</p> <p>Any age: > 7 cm: Further imaging (e.g., MRI) or surgical evaluation</p> | <p>Simple cysts, regardless of age of patient, are almost certainly benign</p> <p>For cysts ≤ 3 cm in women of reproductive age, it is at discretion of interpreting physician whether to describe them in imaging report</p> |
| <p>Hemorrhagic cyst</p> <ul style="list-style-type: none"> • Reticular pattern of internal echoes • +/- Solid appearing area with concave margins • No internal flow |  | <p>Reproductive age: ≤ 5 cm: Not needed > 5 cm: 6-12 week follow-up to ensure resolution</p> <p>Early PM: Any size: Follow-up to ensure resolution</p> <p>Late PM: Consider surgical evaluation</p> | <p>Use Doppler to ensure no solid elements</p> <p>For cysts ≤ 3 cm in women of reproductive age, it is at the discretion of interpreting physician whether to describe them in imaging report</p> |
| <p>Endometrioma</p> <ul style="list-style-type: none"> • Homogeneous low level internal echoes • No solid component • +/- Tiny echogenic foci in wall |  | <p>Any age: Initial follow-up 6-12 weeks, then if not surgically removed, follow-up yearly</p> | |
| <p>Dermoid</p> <ul style="list-style-type: none"> • Focal or diffuse hyperechoic component • Hyperechoic lines and dots • Area of acoustic shadowing • No internal flow |  | <p>Any age: If not surgically removed, follow-up yearly to ensure stability</p> | |
| <p>Hydrosalpinx</p> <ul style="list-style-type: none"> • Tubular shaped cystic mass • +/- Short round projections "beads on a string" • +/- Waist sign (i.e. indentations on opposite sides). • +/- Seen separate from the ovary |  | <p>Any age: As clinically indicated</p> | |
| <p>Peritoneal inclusion cyst</p> <ul style="list-style-type: none"> • Follow the contour of adjacent pelvic organs • Ovary at the edge of the mass or suspended within the mass • +/- Septations |  | <p>Any age: As clinically indicated</p> | |